

The Association between Patent Ductus Arteriosus and Perinatal Infection in A Group of Low Birth Weight Preterm Infants

Edmond Pistulli¹, PhD; Arjan Hamiti¹, MD; Sokol Buba², MD; Alketa Hoxha¹, MD; Nita Kelmendi³, MD; Gentian Vyshka^{*4}, PhD

¹Faculty of Technical and Medical Sciences, University of Tirana, ²University Hospital Center "Mother Teresa", ³University of Prishtina, Kosovo, ⁴Faculty of Medicine, University of Tirana, Albania

Received: May 09, 2013; Accepted: Oct 11, 2013; First Online Available: Nov 22, 2013

Abstract

Objective: Patent ductus arteriosus (PDA) is an extremely common occurrence in very premature infants. Untreated symptomatic PDA may be associated with chronic lung disease. PDA has a major role in neonatal mortality and morbidity. We compared the efficacy and safety of oral versus intravenous ibuprofen for the pharmacological closure of PDA in low birth weight (LBW) preterm infants.

Methods: A randomized, single-blinded, controlled study was performed on premature neonates at the neonatal unit, University Hospital for Obstetrics and Gynecology "Koço Gliozheni", Tirana, Albania from January 2010 to December 2012. The study enrolled 68 preterm infants with a confirmed and significant PDA. The preterm infants received either intravenous or oral ibuprofen randomly as an initial dose of 10 mg/kg, followed by 5 mg/kg at 24 and 48 h.

Findings: 36 patients were treated with oral ibuprofen and 32 with intravenous ibuprofen during this period. After the first course of the treatment, the PDA closed in 30 (83.3%) of the patients assigned to the oral ibuprofen group versus 23 (71.8%) of those enrolled in the intravenous ibuprofen group ($P=0.355$). 15 patients needed a second treatment course and they all (100%) had clinical signs of infection and positive blood culture. There was no reopening of the ductus after the closure.

Conclusion: Our data indicate that, for LBW infants, the rate of early ductal closure was comparable and the adverse effects were fewer with oral ibuprofen in comparison to the intravenous route. Association of PDA with perinatal infection has a negative impact in pharmacological closure of the ductus, increasing the need for a second course of treatment or for surgery.

Iranian Journal of Pediatrics, Volume 24 (Number 1), February 2014, Pages: 42-48

Key Words: Prematurity; Perinatal Infection; Patent Ductus Arteriosus; Oral Ibuprofen; Intravenous Ibuprofen

Introduction

Patent ductus arteriosus (PDA) is extremely common in very premature infants and untreated symptomatic PDA may be associated with chronic lung disease^[1]. Clinical and epidemiological data strongly suggest that infections, either prenatal or

nosocomial, and the presence of a patent ductus arteriosus (PDA) play a major role in the neonatal mortality and morbidity^[2,3,4]. For this reason, efforts to prevent this complication in low birth weight infants should include an aggressive approach to the prevention and treatment of prenatal and neonatal infections and an early

* Corresponding Author;

Address: Lagja 1, Rr. Kostaq Cipo, Tirana 1005, Albania

E-mail: gvyshka@yahoo.com

© 2014 by Pediatrics Center of Excellence, Children's Medical Center, Tehran University of Medical Sciences, All rights reserved.

closure of the PDA. Pharmacological closure of PDA with indomethacin or with ibuprofen, that are both prostaglandin inhibitors, has remained the mainstay of treatment in premature infants over the last three decades^[5,6].

During the search for an explanation of the interaction between neonatal infection and PDA, is observed that the presence of a systemic infection in the premature infant adversely affects permanent closure of the ductus, often inducing ductal opening after the first week of life and failure to respond to medical treatment with indomethacin^[7]. A likely explanation for this interaction is the elevated serum levels of prostaglandins and tumor necrosis factor (TNF) observed in infants with infections. In addition, infants with serious infections frequently have complications that prevent or delay the medical or surgical treatment of the PDA.

As a result, the ductus remains open for prolonged periods of time, maintaining an increased pulmonary blood flow, high capillary pressure, and increased lung fluid. Furthermore, when both complications (infection and PDA) occurred at the same time, they produced a synergistic interaction, further increasing the risk for developing chronic lung disease (CLD)^[10]. As a consequence of the left-to-right shunting through the PDA, pulmonary blood flow and lung fluid increases, negatively affecting lung function and gas exchange, and thereby increasing the risk for CLD^[9]. The presence of a PDA has also been associated with elevated concentrations of myeloperoxidase in the tracheobronchial fluid, suggesting that the increased pulmonary blood flow may result in damage of the pulmonary endothelium and adhesion and migration of polymorphonuclear cells (PMNs) into the lung tissue^[7,8]. Considerable biological plausibility thus exists to explain the influence of significant PDA and sepsis on feed tolerance in preterm neonates. PDA and sepsis are possibly markers of prematurity, and a prolonged interval between starting feeding and full enteral nutrition simply reflects the reluctance to start or continue feeding in the presence of such perceived risk factors for food intolerance and necrotizing enterocolitis (NEC)^[11,12].

In this study, we compared the efficacy and safety of oral versus intravenous ibuprofen for the pharmacological closure of PDA in low

birth weight (LBW) preterm infants.

Subjects and Methods

The study was designed as a prospective, randomized, single-blinded study. The study was conducted in the neonatal intensive care unit of the University Hospital for Obstetrics and Gynecology "Koço Gliozheni", Tirana, Albania, between January 2010 to December 2012. This study was approved by the Medicine University and Neonatology Department.

The study enrolled preterm infants with a gestational age 28-32 weeks, birth weight ≤ 2000 g, postnatal age 48-96 hours, respiratory distress syndrome (RDS) treated with mechanical ventilation (CPAP [continuous positive airway pressure] or IPPV [intermittent positive pressure ventilation]) with additional oxygen requirements above 30% and one of the following echocardiographic criteria: a ductal size >1.5 mm, a left atrium-to-aorta ratio >1.4 , and a left-to-right shunting of blood in addition to signs of PDA. Several sources have used a similar cutoff in the value of PDA, with inclusion of patients whose ductus' diameter was more than 1.5 mm, although no general consensus is achieved^[4-6].

2D (two-dimensional) echocardiography was performed with an ALOKA ultrasound machine (Hitachi), with 5 and 7.5 MHz electronic sector transducers. Gestational age (GA) was assessed by obstetrical dating criteria or, when obstetrical data was inadequate, by Ballard examination.

Exclusion criteria were major congenital abnormalities, right-to-left ductal shunting, life-threatening infection, grade 3 or 4 intraventricular hemorrhage, oliguria of less than 1 ml/kg/h during the preceding eight hours, serum creatinine concentration in excess of 1.6 mg/dl, blood urea nitrogen in excess of 60 mg/dl, thrombocyte count of less than 60 000/mm³, clinical bleeding tendency as revealed by hematuria, blood in the gastric aspirate or in the stools, blood in the endotracheal tube aspirate, oozing from venous or capillary puncture sites, hyperbilirubinemia for which exchange transfusion was required and pulmonary hypertension (Fig. 1).

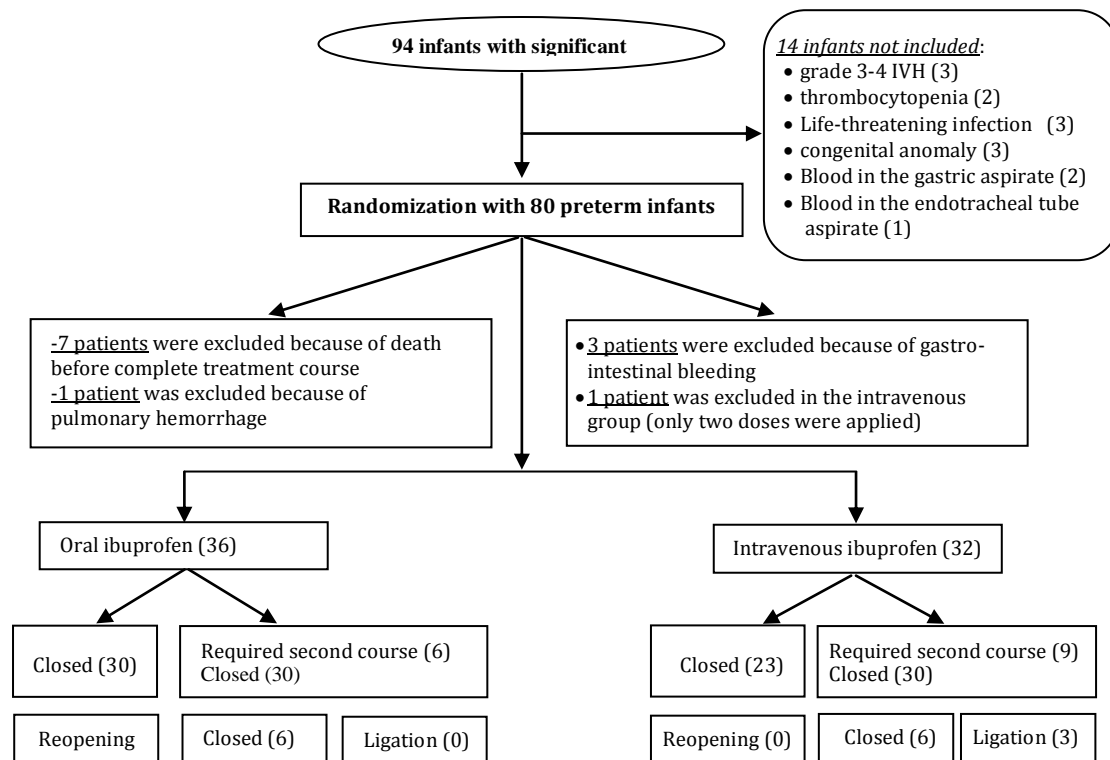


Fig. 1: Flow chart of the study

All infants who met the inclusion criteria first underwent echocardiography and cranial ultrasonography, after which they were treated with oral ibuprofen (Brufen, Abbot S.r.l.; Italy). Ibuprofen in a dose of 10 mg/kg was given via an orogastric tube, flushed with 1 mL of sterile water to ensure delivery of the drug, otherwise an intravenous route was used (Pedia, Orphan Europe; a vial of 2 mL containing 10 mg of ibuprofen), with ibuprofen infused over a 15-minute period with a syringe pump, and the line was subsequently flushed with saline.

The two imaging procedures were performed again 24 hours after each ibuprofen dose. When the PDA was still hemodynamically significant, as demonstrated by echocardiography, and there was no evidence of deterioration in brain ultrasonography, a second dose of ibuprofen 5 mg/kg was administered. A third equivalent dose was given after another 24 hours if deemed necessary. Cranial ultrasound was repeated one week after the last ibuprofen dose and again before discharge from the ward.

RDS was treated with respiratory support (CPAP, IPPV or with high-frequency ventilation), oxygen supplements, and surfactant (Curosurf,

Chiesi, Italy; a vial of 1.5 mL containing 120 mg) was administered intratracheally at the dosage of 100 to 200 mg/kg. Prophylactic antibiotics were started on admission and stopped after five days if blood cultures were negative.

Occurrence of any of the following conditions was enough to discontinue treatment: IVH intraventricular hemorrhage (IVH) grade 3–4, renal failure, NEC, and presence of GEB (gastrointestinal bleeding).

Before and 24 hours after treatment, all patients were evaluated with a complete blood count, renal function tests (serum creatinine level, blood urea nitrogen and urine output), cranial ultrasonography, and echocardiography. All infants continued their current enteral feeding during the treatment.

Findings

A total of 168 premature infants at gestational age <32 weeks and birth weight <2000g and RDS were admitted to our NICU (neonatal intensive care

unit), from January 2010 to December 2012 and underwent an echocardiographic Doppler ultrasound evaluation at the age of 48-96 hours. The entire study protocol was completed for 80 patients due to drop-out related to various reasons (Fig. 1).

We had a minimum value of PDA of 1.5 mm (as inclusion criteria) and a maximum of 3.4 mm (average 2.2 mm; standard deviation ± 0.6 mm).

All premature infants that resulted with a PDA during 48-96 hours of life were treated for three consecutive days with three doses of ibuprofen (dosages and routes described above). 24 hours after the third dose, an echocardiography was performed, and if PDA persisted, a second course of ibuprofen treatment with three other doses was given. Patients with persistent PDA even after the second course were surgically treated. As a result, the closure time was 4 days for the first responsive group (53 patients [30 treated orally and 23 intravenously], see graphics below); 7 days for the responsive group undergoing the second course of treatment (15 patients in total); and the time of surgery for completely non-responsive patients (3 patients undergoing ligation).

After the first course of the treatment, PDA was closed in 30 (83.3%) of the patients assigned to the oral ibuprofen group versus 23 (71.8%) of those enrolled in the intravenous ibuprofen group. Six (16.6%) patients in the oral ibuprofen group required a second course of drug therapy, compared with 9 (28.1%) in the intravenous ibuprofen group. 15 patients needed a second treatment course and they had all (100%) clinical signs of infection and positive blood culture. The

cumulative closure rates were higher in both groups, and only three (9.3%) patients in the intravenous ibuprofen group had surgical ligation. There was no reopening of the ductus after closure was achieved. Baseline characteristics were similar between the two groups in the first 96 hours (Table 1). In the evaluation of renal tolerance, none of the patients had oliguria.

The serum creatinine levels and plasma blood urea nitrogen after the treatment did not differ significantly between the groups (Table 2).

Discussion

Intravenous ibuprofen is not available in most countries (and in our country too), and is more expensive than the oral form. If oral ibuprofen was as efficient as intravenous ibuprofen with no greater adverse effects, the more simple administration and lower cost would be important advantages. Our study was designed with sufficient power for determining whether oral and intravenous ibuprofen treatments are equally efficacious and safe in PDA closure in premature infants with RDS. Our results showed oral ibuprofen to be effective and safe in PDA closure, with 30 of our 36 (83.3%) study infants achieving a successful outcome. The rate of closure in the group assigned to intravenous ibuprofen was similar to rates previously reported^[4,11]. Some trials on the use of oral ibuprofen for closure of PDA have been recently published^[14,15,21]. All

Table 1: Baseline characteristics of the low birth weight preterm infants in oral vs intravenous ibuprofen therapy

Variable	Oral (n = 36)	Intravenous (n= 32)
Gestational age, weeks	28.1 – 30 weeks	19 (52.7%)
	30.1 – 32 weeks	17 (47.2%)
Birth weight, grams	<750g n (%)	2 (5.5%)
	751-1000g n (%)	7 (19.4%)
	1001-1500g n (%)	15 (41.6%)
	1501-2000g n (%)	12 (33.3%)
Gender	Male, n (%)	22 (61.1%)
	Female, n (%)	14 (38.8%)
Delivery by cesarean section, n (%)	20 (55.5%)	14 (43.7%)
Antenatal glucocorticoid treatment, number and percentage (%)	28 (77.7%)	18 (56.2%)
Perinatal asphyxia, n (%)	11 (30.5%)	9 (28.1%)

Table 2: Biochemical values in two group low birth weight preterm infants in oral vs intravenous ibuprofen therapy

Parameters		Oral group (n=36)	Intravenous group (n= 32)	P. value
Plasma blood urea nitrogen (mg/dl) (mean ± SD)	Day 1	30.7 (14.8)	30.4 (13.7)	.90
	Day 2	30.3 (14.2)	30.6 (14.0)	.89
	Day 3	30.88 (7.76)	31.66 (9.90)	.68
Mean plasma creatinine (mg/dL) (mean±SD)	Day 1	1.07 (0.24)	1.09 (0.24)	.06
	Day 2	1.20 (0.95)	0.97 (0.45)	.07
	Day 3	0.76 (0.48)	0.79 (0.46)	.07
Oligo/anuria (ml/kg/h)	Day 1	0 (0%)	0 (0%)	
	Day 2	0 (0%)	0 (0%)	
	Day 3	0 (0%)	0 (0%)	
Infection and need for a second treatment course		6 (16.6%)	9 (28.1%)	
Need for surgical ligation		0 (0%)	3 (9.3%)	

studies had small sample size. Aly^[16] in a randomized pilot study, reported that PDA was closed in 7 of 9 premature (≤ 35 weeks) infants given oral ibuprofen and in 10 of 12 premature infants given intravenous indomethacin.

Fakhraee^[22] in a randomized study, reported that PDA was closed in all of 18 premature (≤ 34 weeks) infants given oral ibuprofen and in 15 of 18 premature infants given oral indomethacin ($P > .05$). Efficacy of oral ibuprofen compared with intravenous indomethacin, was reported by Supannachart et al^[23] and Chotigeat et al^[24] as well. In nonrandomized open trials, Heyman et al^[25] and Cherif et al^[18] reported a ductal closure with oral ibuprofen respectively in 21 (95.4%) of 22 patients, 38 (95%) of 40 patients, and in 11 (84.6%) of 13 patients. The authors concluded that oral ibuprofen might constitute a feasible alternative in the treatment of PDA. Van Overmeire et al studied the efficacy of indomethacin and ibuprofen given to larger premature (≤ 32 weeks) infants at the age of 2-4 days. They reported that the closure rate was similar (66% and 70%, respectively) after the first course and that there was no significant difference in side effects, although ibuprofen was associated with significantly less impairment of renal function^[11,25]. Two studies increase the number of infants randomized and expand the information about the safety and efficacy of oral ibuprofen in more mature VLBW (very low birth weight) infants^[19,20]. We hope the same for our study.

Since renal tolerability of ibuprofen on renal function in the neonate is a major argument in favor of its use in the treatment of PDA^[19,20] our study expands our information about the safety

and efficacy of oral ibuprofen in more mature VLBW infants.

Serum creatinine and urea levels in our patients were within normal range at all times, so there was no contraindication for a second dose of ibuprofen when it was needed. This might be an explanation for the higher rate of pharmacologic ductal closure observed in our study.

Gonzales et al showed that late PDA episodes were more frequent in infants with infection than in those without infection and were associated with an increased risk of PDA closure failure. Furthermore, when both factors were temporally related, they further increased the risk of CLD^[5,7].

There are several limitations to our study. This was an open-label, one-arm study, and the physicians and nurses were aware of the nature of the study, although the cardiologist who supervised the echocardiographic studies was blinded as with regard to the status of the infants, and whether they were treated with oral ibuprofen or intravenous ibuprofen. On the other hand, being not a hemodynamic study, we could not obtain pressure values of the heart chambers (systolic and diastolic pressures, TR pressure gradients, pulmonary artery pressure); such a data collection would have surely enhanced the value of our conclusions. The exclusion of PDA patients whose ductal size was less than 1.5 mm might be another limitation, although several sources use such a cutoff^[4-6]. This is not simply related to the fact that a smaller ductal size might be not important hemodynamically, and other authors do consider, although through the denomination 'mild', the hemodynamic importance even of a ductal size of less than 1.5

mm^[26]. The problem of visualizing a patent ductus and thus differentiating it from a closed ductus when values are less than 1.5 mm remains however, a technical challenge^[27]. This technicality might be overcome through using a 3D (three-dimensional) echocardiography, with higher spatial resolution and a better diagnostic accuracy^[28].

This is the first experience that we have had in Albania with ibuprofen (oral or intravenous) regarding the treatment of PDA in preterm infants.

Conclusion

Our data indicate that, for preterm infants especially for LBW infants, the rate of early ductal closure was comparable and the adverse effects were fewer with oral ibuprofen in comparison to the intravenous route. Association of PDA with perinatal infection has a negative impact on the pharmacological closure of the ductus, increasing need for a second course and for surgical ligation. The oral form was as safe as the intravenous form in terms of renal tolerance. Larger comparative studies are needed to validate these findings.

Authors' Contribution

E. Pistulli concept and manuscript preparation, data analysis and interpretation.

A. Hamiti, S. Buba, A. Hoxha and N. Kelmendi acquisition of data, data analysis and interpretation.

G. Vyshka manuscript preparation and critical revision of the manuscript.

All authors have approved the final version of the paper.

Conflict of Interest: None

References

- Noori S, McCoy M, Friedlich P, et al. Failure of ductus arteriosus closure is associated with increased mortality in preterm infants. *Pediatrics* 2009;123(1):e138-44.
- Fanaroff AA, Stoll BJ, Wright LL, et al. Trends in neonatal morbidity and mortality for very low birthweight infants. *Am J Obstet Gynecol* 2007;196(2):147.e1-8.

- Van Overmeire B, Chemtob S. The pharmacologic closure of the patent ductus arteriosus. *Semin Fetal Neonatal Med* 2005;10(2):177-84.
- Bersani I, De Carolis MP, Lacerenza S, et al. Is the prophylaxis of patent ductus arteriosus useful in extremely premature infants? *Turk J Pediatr* 2011;53(2):187-93.
- Sekar KC, Corff KE. Treatment of patent ductus arteriosus: indomethacin or ibuprofen? *J Perinatol* 2008;28(Suppl 1):S60-2.
- Yang EM, Song ES, Choi YY. Comparison of oral ibuprofen and intravenous indomethacin for the treatment of patent ductus arteriosus in extremely low birth weight infants. *J Pediatr (Rio J)* 2013;89(1):33-9.
- Gonzalez A, Sosenko IRS, Chandar J, et al. Influence of infection on patent ductus arteriosus and chronic lung disease in premature infants weighting 1000 grams or less. *J Pediatr* 1996;128(4):474-8.
- Varsila E, Hallman M, Venge P, et al. Closure of patent ductus arteriosus decreases pulmonary Myeloperoxidase in premature infants with respiratory distress syndrome. *Biol Neonate* 1995;67:167-71.
- Herson VC, Krause PJ, Eisenfeld LI, et al. Indomethacin-associated sepsis in very-low-birth-weight infants. *Am J Dis Child* 1988;142(5):555-8.
- Patole SK, Muller R. Enteral feeding of preterm neonates: a survey of Australian neonatologists. *J Matern Fetal Neonatal Med* 2004;16(5):309-14.
- Gournay V, Roze JC, Kuster A, et al. Prophylactic ibuprofen versus placebo in very premature infants: a randomized, double-blind, placebo-controlled trial. *Lancet* 2004;364(9449):1939-44.
- Richards J, Johnson A, Fox G, et al. A second course of ibuprofen is effective in the closure of a clinically significant PDA in ELBW infants. *Pediatrics* 2009;124(2):e287-93.
- Shah SS, Ohlsson A. Ibuprofen for the prevention of patent ductus arteriosus in preterm and/or low birth weight infants. *Cochrane Database Syst Rev* 2006;(2):CD004213.
- Cherif A, Jabnoun S, Khrouf N. Oral ibuprofen in early curative closure of patent ductus arteriosus in very premature infants. *Am J Perinatol* 2007;24(6):339-45.
- Sangtawesin V, Sangtawesin C, Raksasinborisut C, et al. Oral ibuprofen prophylaxis for symptomatic patent ductus arteriosus of prematurity. *J Med Assoc Thai* 2006;89(3):314-21.
- Aly H, Lotfy W, Badrawi N, et al. Oral ibuprofen and ductus arteriosus in premature infants: a randomized pilot study. *Am J Perinatol* 2007;24(5):267-70.
- Patel J, Roberts I, Azzopardi D, et al. Randomized double-blind controlled trial comparing the effects of ibuprofen with indomethacin on cerebral hemodynamic in preterm infants with patent ductus arteriosus. *Pediatr Res* 2000;47(1):36-42.

18. Cherif A, Khrouf N, Jabnoun S, et al. Randomized pilot study comparing oral ibuprofen with intravenous ibuprofen in very low birth weight infants with patent ductus arteriosus. *Pediatrics* 2008;122(6):e1256-61.
19. Gokmen T, Erdeve O, Altug N, et al. Efficacy and safety of oral versus intravenous ibuprofen in very low birth weight preterm infants with patent ductus arteriosus. *J Pediatr* 2011;158(4):549-54 e1.
20. Erdeve O, Gokmen T, Altug N, et al. Oral versus intravenous ibuprofen: which is better in closure of patent ductus arteriosus? *Pediatrics* 2009;123(4):e763.
21. Hariprasad P, Sundarrajan V, Srimathy G, et al. Oral ibuprofen for closure of hemodynamically significant PDA in premature neonates. *Indian Pediatr* 2002;39(1):99-100.
22. Fakhraee SH, Badiie Z, Mojtahedzadeh S, et al. Comparison of oral ibuprofen and indomethacin therapy for patent ductus arteriosus in preterm infants. *Zhongguo Dang Dai Er Ke Za Zhi* 2007;9(5):399-403.
23. Supapannachart S, Limrungsikul A, Khowsathit P. Oral ibuprofen and indomethacin for treatment of patent ductus arteriosus in premature infants: a randomized trial at Ramathibodi Hospital. *J Med Assoc Thai* 2002;85(Suppl 4):S1252-8.
24. Chotigeat U, Jirapapa K, Layangkool T. A comparison of oral ibuprofen and intravenous indomethacin for closure of patent ductus arteriosus in preterm infants. *J Med Assoc Thai* 2003;86(Suppl 3):S563-9.
25. Heyman E, Morag I, Batash D, et al. Closure of patent ductus arteriosus with oral ibuprofen suspension in premature newborns: a pilot study. *Pediatrics* 2003;112(5):e354.
26. Sasi A, Deorari A. Patent ductus arteriosus in preterm infants. *Indian Pediatr* 2011;48(4):301-8.
27. Sahn DJ, Allen HD. Real-time cross-sectional echocardiographic imaging and measurement of the patent ductus arteriosus in infants and children. *Circulation* 1978;58(2):343-54.
28. Roushdy A, Fiky AE, Din DE. Visualization of patent ductus arteriosus using real-time three-dimensional echocardiogram: Comparative study with 2D echocardiogram and angiography. *J Saudi Heart Assoc* 2012;24(3):177-86.