

## Tumoral calcinosis of bilateral hip joint in an adult female: A Case report

**Authors:** F. Byiringiro Mugabe<sup>1,\*</sup>; B. Rugwizangoga<sup>2</sup>

**Affiliations:** <sup>1</sup>Department Department of Clinical Biology, School of Medicine and Pharmacy, University of Rwanda, Kigali Rwanda; <sup>2</sup>Department of Pathology, University Teaching Hospital of Kigali, Kigali Rwanda

### INTRODUCTION

The term Tumoral Calcinosis (TC) was coined by Inclin in 1943 but similar pathological entities were recognized in the late 1890s [1,2]. It is a rare condition consisting of accumulation of calcium in periarticular tissue outside of capsule. Most commonly it involves large joints (hip, shoulder and elbow). Less commonly, hands and wrist joints may be involved with this process. Most patients with TC are in the first two decades of life. There is not gender difference, i.e. the male to female ratio is 1:1 [1]. Tumoral Calcinosis cases fall into two broad categories: Primary Tumoral Calcinosis (PTC) and Secondary Tumoral Calcinosis (STC). Patients in the latter group usually have chronic renal failure. The radiographic features and the histopathology of the two groups are similar. The two groups are dissimilar in their biochemical markers and genetic features. Both medical and surgical treatment have a place in the management of patients with this unusual disease or group of diseases.

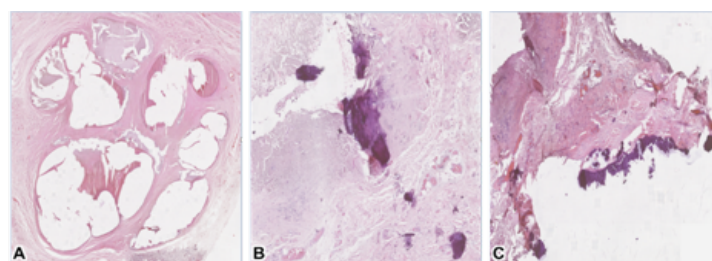
**Keywords:** Calcinosis; Tumoral; Hip Joint; Histology; Rwanda

### CASE PRESENTATION

The patient was a 64-year old female with no known background of trauma or recurrent pressure, presented with a twenty-year history of progressive well circumscribed, hard and fixed bilateral masses of variable sizes ranging from 2x1cm to 3x2.5cm located on the buttocks adjacent to her hip joints. Complete blood count was normal, HIV test was negative, and blood group was O+. Because of the extremely limited resources at both the health facility where this patient was initially seen and the regional hospital where she was referred, no further diagnostic tests were performed. Both masses were excised and the specimens was sent to a teaching hospital for histopathological analysis.

Grossly, there were two tan-whitish, firm to hard nodular fragments of tissue; the biggest measures 3.5x2x1.5cm, the smallest measures 2x1.5x1cm and cut sections is done to reveal whitish solid and cystic surfaces. Microscopically, haematoxylin

and eosin (H&E)-stained sections showed heterogeneous lesions composed of large cystic cavities without lining epithelium (Figure 1A). Some of these lining cavities contained calcified materials (Figure 1B). Other areas showed fibrotic tissue mixed with calcifications (Figure 1C). These findings were consistent with the diagnosis of tumoral calcinosis.



**Figure 1. Photomicrographs of a case of tumoral calcinosis**  
**A)** Heterogeneous cystic cavities without true lining epithelium (H&E stain, 40X); **B)** calcium filled cystic cavities (H&E stain, 40X); **C)** Fibrosis admixed with calcifications (H&E stain, 40X).

\*Corresponding author: Fiacre BYIRINGIRO MUGABE, fiacremugabe@gmail.com; **Potential Conflicts of Interest (Col):** All authors: no potential conflicts of interest disclosed; **Funding:** All authors: no funding was disclosed; **Academic Integrity:** All authors confirm that they have made substantial academic contributions to this manuscript as defined by the ICMJE; **Ethics of human subject participation:** The study was approved by the local Institutional Review Board. Informed consent was sought and gained where applicable;

**Originality:** All authors: this manuscript is original has not been published elsewhere; **Type-editor:** Matthew Cardilo (USA)

**Review:** This manuscript was peer-reviewed by three reviewers in a double-blind review process;

**Received:** 15th May 2019; **Initial decision given:** 19th May 2019; **Revised manuscript received:** 26th May 2019; **Accepted:** 27th May 2019

**Copyright:** © The Author(s). This is an Open Access article distributed under the terms of the Creative Commons Attribution License (CC BY-NC-ND) (click here), which permits unrestricted use, distribution, and reproduction in any medium, provided the original work is properly cited. **Publisher:** Rwanda Biomedical Centre (RBC)/Rwanda Health Communication Center, P.O.Box 4586, Kigali.

**ISSN:** 2079-097X (print); 2410-8626 (online)

**Citation for this article:** F. Byiringiro Mugabe; B. Rugwizangoga. Tumoral calcinosis of bilateral hip joint in an adult female: A Case report. Rwanda Medical Journal, Vol 76, no 4, pp 1-2, 2019

## DISCUSSION

Tumoral calcinosis is a rare form of ectopic calcification characterized by large, rubbery, or cystic masses occurring mainly around large joints such as hip, shoulder, and elbow. It can also occur in the small joints of the hand and foot [3].

Primary tumoral calcinosis is an autosomal dominant recessive metabolic disorder [4]. Secondary tumoral calcinosis is a disorder in calcium metabolism usually related to chronic renal failure. The primary variety of the disease is mainly described young African-American adults [2]. The identified major genes responsible are GALNT3, FGF-23, and Klotho [2] - three genes whose proteins are important in promoting phosphate excretion and suppressing vitamin D synthesis. The age group ranges between 15 and 70 years with no sex predilection [3].

Secondary tumoral calcinosis occurs most commonly in patients with chronic renal failure but also is seen in other disorders in calcium metabolism hyperparathyroidism, vitamin D intoxication, excessive milk consumption, collagen diseases (e.g. scleroderma), and bony destruction secondary to malignancy. Complete surgical excision is usually recommended in patients with primary tumoral calcinosis but surgical complications such as wound infections and chronic draining sinuses are common.

For the present case, the patient was felt to likely have primary tumoral calcinosis, since there was no renal failure or any other metabolic disorder recorded. Treatment of the underlying medical condition is usually recommended in patients with secondary tumoral calcinosis. An important exception to this principle is

that parathyroidectomy may be indicated in patients with primary or secondary hyperparathyroidism. Periarticular calcification is a consistent histopathological finding in tumoral calcinosis. Other supportive diagnostic findings are the amorphous granular nature of the calcific material and the absence of crystal deposits. In our case, cystic changes without true lining epithelium and fibrosis (may be secondary to previous healed traumatization of the lesion) and scattered neutrophilic component were also features. Cartilage and synovium are not normally found in the lesion itself in cases of TC.

Tumoral calcinosis is a rare clinicopathological entity with readily recognizable radiographic and histopathological findings. Management of this condition is dependent upon the patient's functional disability and whether the condition is primary or secondary.

## REFERENCES

1. Fathi I, Sark M. Review of tumoral calcinosis: A rare clinico-pathological entity. *World J Clin Cases* . 2014;2(9):409-41.
2. Xu C, Potter J A, Carter C D, Lang C M. Idiopathic Tumoral Calcinosis in Hand : A Case Report. *Eplasty* 2014 Jul 24;14:e28.
3. Gali B, Nggada H, Mshelia D. A Clinicopathological Pattern Of Tumoral Calcinosis In Maiduguri, North Eastern Nigeria. *The Internet Journal of Third World Medicine* 2005;3(2):2-5.
4. Topaz O, Shurman DL, Bergman R, Indelman M, Ratajczak P, Mizrachi M, et al. Mutations in GALNT3, encoding a protein involved in O-linked glycosylation, cause familial tumoral calcinosis. *Nat Genet*. 2004;36(6):579-81.